

Photographs of Medical Casuistry in the Croatian Journal *Liječnički vjesnik* from 1877 to 1949

Fatović-Ferenčić, Stela; Kuhar, Martin

Source / Izvornik: **Formats of (Non)Seeing, 2024, 20 - 49**

Conference paper / Rad u zborniku

Publication status / Verzija rada: **Published version / Objavljena verzija rada (izdavačev PDF)**

<https://doi.org/10.31664/9789533730530.02>

Permanent link / Trajna poveznica: <https://um.nsk.hr/um:nbn:hr:254:597274>

Rights / Prava: [In copyright](#)/[Zaštićeno autorskim pravom.](#)

Download date / Datum preuzimanja: **2025-03-29**



Repository / Repozitorij:

[PODEST - Institute of Art History Repository](#)

DOI: 10.31664/9789533730530.02

After the discovery of photography, scientists almost immediately recognized its potential in different fields of research including medicine. From very early days, doctors were involved in applying photography as a tool for documenting clinical cases, helping them make a correct diagnosis and reaching valid conclusions in clinical research.² In Parisian hospital Charité in 1840, Alfred François Donné photographed bones and teeth and made daguerreotypes from microscopic images.³ In 1852, the founder of Berlin's orthopedic clinic Hermann Wolff Berend started to photograph patients before and after operations.⁴ Hugh Welch Diamond, the founder of the Photographic Society, used photography to identify visual signs of mental illness and thus study its physiognomy.⁵ Guillaume-Benjamin Duchenne recorded photographically the effect of facial muscle faradization and the most typical pathological cases, which resulted in the *Album de photographies pathologiques* published in 1862, the first attempt to illustrate a medical book with photographs of living patients.⁶ His student at the Salpêtrière hospital Jean-Martin Charcot believed that photographs could help the doctors diagnose and understand mental illnesses, particularly hysteria.⁷ In 1882, Charcot employed Albert Londe who, as a result of his involvement, published *La photographie médicale* in 1893.⁸ Photography also became an instrumental element in the development of medical disciplines such as dermatology. At the same time, it spurred the establishment of journals entirely devoted to medical photography, with the first being the *Revue photographique des hôpitaux de Paris. Bulletin Médical* founded in 1869.⁹

- 1 This paper is an expanded version of a paper currently in print in *Liječnički vjesnik*.
- 2 Rosen, "Medicine and Early Photography".
- 3 Diamantis, Magiorkinis, Androutsos, "Alfred François Donné".
- 4 Summerly, "Medical Photography", 916.
- 5 Wetzler, "Hugh Diamond".
- 6 Parent, "Duchenne De Boulogne", 373.
- 7 Didi-Huberman, *Invention of Hysteria*; Hustvedt, *Medical Muses*.
- 8 Brauer, "Capturing Unconsciousness".
- 9 Pasquali, "History of Medical Photography".

In the nineteenth century, professional journals became widely available and increasingly influential, particularly for the dissemination of new knowledge and clinical experiences, thus gathering members of various medical specialties in a community of shared interests. Medical journals developed into influential forums that stimulated the development of medical professions, modified the scientific landscape and even effected societal changes. It is believed that the number of scientific journals increased from 900 in 1800 to 60.000 in 1901.¹⁰

Among the first medical journals in Croatia was *Liječnički vjesnik*, the official bulletin of the Croatian Medical Association established in 1877. In time, this journal developed into a recognizable platform fostering local development of clinical medicine and scientific research, and is now among only a hundred oldest European journals that are published in continuity to this day. This continuity counting 146 years enables multiple insights, including the changes in editorial policies and the shifting healthcare interests, as well as the reconstruction of how broader political, social and cultural contexts influenced medical landscape in the country.¹¹ At the same time, its pages allow us to trace the advent and development of medical photography, their quality, content and functionality.

LJEČNIČKI VJESNIK AND MEDICAL PHOTOGRAPHY IN CROATIA

There is almost no medical specialty that remained apathetic towards the use of photography.¹² However, works that analyze and interpret the role of medical photography in shaping ideas on health, medical innovations and scientific breakthroughs in Croatia are rather rare. There is an analysis on the pioneering work of traumatologist Vatroslav Florschütz which extensively utilized a collection of photographs on glass that documented his operating practices.¹³ Recently, an analysis was published on Božidar Špišić, the pioneer of clinical photography in Croatia, who used photography to assert the social importance of orthopedics in treating injured soldiers during the First World War.¹⁴ Photographs preserved at the Croatian Museum of Medicine and Pharmacy were used in two studies: first, on the connection between tuberculosis and housing misery in Zagreb in the early interwar period,¹⁵ and second on the visual memory of the otorhi-

10 Brodman, *The Development of Medical Bibliography*.

11 Fatović-Ferenčić, *Liječnički vjesnik*.

12 See, for example, Hannavy, *Encyclopedia*; Neuse et al., "The History of Photography in Dermatology"; Milam, Ramachandran, "Dermatologic Atlases"; Rogers, "The First Pre- and Post-Operative Photographs"; Parent, "Duchenne de Boulogne".

13 Fatović-Ferenčić, Pećina, *Iz Florschützova okvira*.

14 Fatović-Ferenčić, Kuhar, "Photography in the Rehabilitation".

15 Fatović-Ferenčić, Brkić Midžić, "Fotografije zagrebačke stambene bijede"; Fatović-Ferenčić, Kuhar, "The Representations of Housing Conditions and Tuberculosis".

nology clinic.¹⁶ Furthermore, photographs kept at the Division for the History of Medical Sciences of the Croatian Academy of Sciences and Arts were used to discover the ways in which the Department of Ophthalmology in Zagreb was visually memorialized.¹⁷ Matko and Ana Marušić outlined the specificities and the role of war photography in the areas of public health, surgery, medical diagnostics, microscopy, psychiatry and forensic medicine,¹⁸ while Dražen Grgić, Ante Pentz and Zdravko Mandić published a paper on digital photographs in ophthalmology.¹⁹ Finally, Marko Velimir Grgić and Marija Pastorčić Grgić wrote a more general analysis on the role of visual documentation in medicine.²⁰

When studying medical photography in professional journals in Croatia it is warranted to start from *Liječnički vjesnik*. At the time of its establishment, there was no medical school in Croatia and medical publications such as textbooks were scarce. The journal attempted to compensate for these deficiencies by encompassing a broad range of topics, many of which were accompanied by visual material such as drawings, X-rays and photographs. After the establishment of the School of Medicine in Zagreb in 1917, this journal transformed into an influential publication for the sharing of knowledge and clinical experiences within larger medical community.

Aside from changing its content through time, *Liječnički vjesnik* altered its appearance as well. Its visual presentation points not only to the ways the journal was graphically edited in the past, but also reflects the aesthetic sensibilities of different eras. In its beginnings, limited financial means pushed its visual appearance further down the priority list.²¹ The first medical photograph printed in *Liječnički vjesnik* appeared in 1887 in an article entitled *Molluscum pedis cum nuce ossea* (Soft outgrowth with bony nucleus) by Josip Antolković, a secondary physician based at the Brothers of Mercy Hospital in Zagreb. It represents a soft tumor on a 24-year-old male's foot.²² The photograph was printed at the center of the article, pushing into both textual columns. It does not contain a caption because the article is essentially a detailed description of the photograph.

After this photograph, the practice of including visual material in the articles became more prevalent. Photographs of interesting medical cases, apparatuses, medical institutions, departments, micro- and macro-preparations and portraits became a regular part of the journal's content, while

16 Fatović-Ferenčić, Brkić Midžić, "Vizualna memorija struke;" Fatović-Ferenčić, Prgomet, *Vizualna memorija struke*.

17 Fatović-Ferenčić, "The Eye Clinic's Visual History".

18 Marušić, Marušić, "Ratna fotografija u medicini".

19 Grgić, Pentz, Mandić, "Digital Imaging in Ophthalmology".

20 Grgić, Pastorčić Grgić, "Slikovna dokumentacija u medicini".

21 Brkić Midžić, Fatović-Ferenčić, "Vizualni identitet Liječničkog vjesnika".

22 Antolković, "Molluscum pedis".

after the discovery of Röntgen radiation X-ray images were also printed in abundance.

Visual identity of *Liječnički vjesnik* varied widely until 1950, which is also reflected in the ways photographs were included in its articles. At first, the photographs were part of the article as a supplementary material to the text. Their dimensions also varied so they could be found either in the center of the page or by the left or right text margins. From 1924 to 1934 photographs were published in a special supplement to every issue on a glossy white paper. Even when after 1934 the photographs were again printed within the text, sometimes the issues were supplemented with glossy paper at the end, especially in cases of a large number of photographs or when they were particularly striking.

Given the extensive photographic material found in *Liječnički vjesnik*, this analysis is focused on a specific sample concerning only the photographs depicting various types of medical casuistry from 1877 to 1949 (diseases and other pathologies, congenital malformations etc.), excluding X-ray images, therapeutic procedures (such as operations, reductions etc.) and medical institutions (such as hospitals, departments and physicians). Our sample includes a total of 251 cases accompanied by one or more photographs. For the purpose of this paper, we have categorized them as follows: patient portraits, photographs that visualize patients' emotions, photographs of extreme pathologies, photographic sequences and photographs used to assert the importance of particular medical specialties. We will also reflect on the temporality of photographs, their documentary value and the ethical implications that can be extracted from them.

PORTRAIT PHOTOGRAPHS

Several hundreds of identified photographs confirmed our suspicion that a substantial number of them would be portrait photographs. This is understandable given the fact that this was still a time of a holistic view on human health and disease, while the observation of individual variations within generalized parameters was a standard feature of clinical practice. Diagnostic capabilities were only being developed, so taking history and performing detailed physical examination were indispensable in the process of clinical evaluation of the patient. The photographs open the possibility to visualize data and distribute it to the reader. According to Kendall Walton, the authenticity of a photograph brings us closer to the person it represents by providing a sense of closeness—as if we were in contact with that person.²³

At the end of the nineteenth and the beginning of the twentieth centuries, doctors mainly attempted to identify and explore the national pathology, its features and prevalence. Portrait photographs thus revealed patients

23 Walton, "Photographic realism".

with their local specificities and features, such as rural (women with scarves, girls with pigtails), urban (suit and tie, haircut) or military. Their clothes also tell us whether they were treated at the hospital (if they are in pajamas) or in the outpatient department (if they are dressed in a suit).

One of the more striking photographs of this kind is a photograph of a mother with a four-month-old male infant diagnosed as *meningocele occipitalis inferior* (Fig. 1).²⁴ The mother is dressed in black with a black scarf tied on her head. She is calm and composed with lowered eyelids, focusing on the child she holds during the examination. The composition of the photograph is diagonal, while the character of a mother dressed in all black is contrasted with an infant wrapped in white cloth. At the center of the photograph is the child's head in profile with two round protuberances visible in the occipital region. The child's face is illuminated and it calmly looks away from camera. This photograph was taken on November 13, 1902, when the patient was admitted to the hospital. Both mother's and child's calmness is somewhat unexpected and points to the pose created by the photographer to suggest the involvement of the mother in the process of physical examination. Trusting the physicians and hoping for a successful treatment, she willingly surrenders the child to the medical procedure. Her presence gives certain warmth and protection to the child, thus alluding to the humanness present in medicine despite overwhelming paternalism characterizing the first half of the twentieth century. Given its content and composition, this photograph stands out from other depictions of small children and infants which are mostly devoid of parental contact.

Sometimes portrait photography was used to emphasize specific symptoms in diagnosing a disease, thus acquiring a didactic role. An example is a photograph of three naked, skinny boys with protruding bellies on which the doctors drew lines in order to mark the significant enlargement of their livers and spleens. Such photographs were frequently taken during public health campaigns to suppress malaria in Dalmatia at the time and these have become almost paradigmatic for this disease.²⁵ This photograph is subversive, because although it alludes to typical depictions of patients suffering from malaria, it actually shows patients with endemic kala-azar. (Fig. 2).²⁶ By visualizing the same symptoms, the photograph warns about the possibility of mixing those two diseases and the dangers such a mistake brings. Namely, the wrong diagnosis resulted in the application of inadequate therapy, since quinine—a drug used to treat malaria—is ineffective in treating kala-azar, while exposing the children to its many side-effects.²⁷

24 Maixner, "Meningocele occipitalis inferior".

25 Senta Marić, "Arhivska građa", 130.

26 Krmpotić, "Endemija kala-azara".

27 Mayerhofer, Dragišić, "Raširenost Kala-azara".

The tension between objectification of the body and its individuality makes photography a powerful tool when discussing a phenomenon Michel Foucault named the medical gaze.²⁸ The medical system subordinates the patients' emotional reactions to its own need for an objective, analytic assessment, with a focus on the realistic depiction which minimizes the role of photographer as an artist. This is due to the fact that a doctor expects a realistic representation in order to be able to clinically interpret the data. The scenery present in our sample of photographs is thus strictly related to the patients' pathology, while the only décor are white hospital walls and functional pieces of furniture, such as chairs on which the patients lean or sit, metal medical tripods and bandaging tables. Emotions on these photographs are frozen due to the focus—both on the part of a photographer and a patient—on the faithful reproduction of certain pathological changes. Patients' faces either show only glimpses of tension, fear, confusion and worry or they are expressionless and flat. Rarely, however, the photographs captured elements of subjective experience, as in the case of a photographic sequence showing the results of the operation performed on a 27-year-old woman with cleft lip. After the successful operation, the woman gained the functional ability to smile, which is portrayed through her joyous expression of delight at this fact. Her smile thus not only represents a functional ability that she previously did not possess, but also expresses the triumph of medicine (Fig. 3).

In the same way that the décor on these photographs was improvised and secondary to the medical information communicated through them, the photographers also paid little attention to the capturing of what Roland Barthes termed the “essence” of a person.²⁹ Still, in the case of a 24-year-old farmer with ptosis, epicanthus and trachoma, the doctors invoked the readers to try to unearth an essential and invisible part of the personality beyond the physical level, the so-called *animula*. The author of this case report thus invited his readers to observe the “patient's unintelligent gaze”, seemingly established with the presence of epicanthus, a sign accompanying certain hereditary disorders such as the Down syndrome (Fig. 4).³⁰ The photograph, which functions as a tool not only in establishing bodily symptoms but also mental issues, in this case the patient's underdeveloped cognitive dimension, is thus completely in line with popular contemporary theories on the organic basis of mental disorders.

28 Zittlau, “Medical Portrait Photography”.

29 Barthes, *Camera Lucida*, 6.

30 Toth, “Kongenitalna ptoza”.

A significant segment of knowledge in the analyzed period was gained through comparing the pathological and the normal. The clinicians attempted to recognize general patterns and exceptions to the rules, and thus had a tendency to publish cases with rarely seen pathologies, frequently accompanying them with photographs. One such example, which allows for the reconstruction of lay conceptualizations of disease and the widespread custom of avoiding doctors, is a case from Ogulin hospital. There, in 1934, a 21-year-old girl was admitted with a massive vulvar tumor. The girl stated that she first noticed a lump on her right labia major when she was 15, but only went to the doctor six years later when the tumor started to “bother her during walking” and because “as a grown-up woman and a future wife [she] felt ashamed and wanted to get rid of it.”³¹ It is precisely this functional aspect of the tumor, i.e., how it impeded the girl's ability to walk, that the photographer wanted to depict with two photographs. In particular, the second photograph shows the girl with legs brought together in front of which hangs a huge fibromatous tumor that we can easily visualize how it strikes the girl's legs during walking (Fig. 5). Luckily, the hospital surgeon made a simple excision of the tumor that weighed 1700 grams, as well as the aesthetic genital plastic surgery, and the girl was released fully recovered.

The highest number of photographs of rare cases depicted advanced tumors with extreme dimensions. Some of them represented facial defects due to cancers in elderly but also children,³² which additionally emphasized the rarity of such pathological changes. The photographs of rare cases contributed to the definition of *pathological*, constructing at the same time the concept of *normal*. Not only is this visible in cases of tumors, but also in the first cases of female³³ and male hermaphroditism.³⁴ Extremely rare combinations of diseases are also photographed, such as the testicular tuberculosis in a patient with testicular feminization, whose unfortunate diagnosis was reached by observing a mysterious lump in her inguinal canal.³⁵ Such cases confronted Croatian doctors with different, sometimes incompatible classification systems proposed by other, foreign authors. Photographs were used as a tool in convincing the readership as to why a particular system of classification was accepted and others rejected. At the same time, new names for various nosological entities were inaugurated and thus entered clinical practice in Croatia.

Doctors also considered how pathological phenomena corresponded with normal dependent on their quantitative variations.³⁶ A good example of

31 Vodehnal, “Dva rijetka ginekološka slučaja”.

32 Car, “Sarkom der Orbita”.

33 Culek, “Pseudohermafroditismus”.

34 Zanela, “Hermaphroditismus”.

35 Ibid.

36 Zittlau, “Medical Portrait Photography”.

this is a diagnosis of *obesitas universalis*, the proof of which was a photograph of a naked woman (Fig. 6). For the author of the article, who worked in a rural, less developed part of Croatia where sustenance was scarcer, the case was “worthy of special mention” with almost a trivial explanation that “the crucial moment is supposedly chemical, i.e., the production of fat was larger than the expenditure.”³⁷ When we contrast this case with today’s world in which every fifth person in Croatia is obese and that obesity is now strongly correlated with poverty, it is readily apparent that the definition of normal depends in large part on the socioeconomic context, societal norms and the prevalence of certain pathologies.

THE TEMPORALITY OF PHOTOGRAPHS

Writing on the temporality of photographs, Barthes claims that a photograph exposes past in the present, underscoring the inevitable transience.³⁸ The photograph reflects a segment in time marked with a certain experience and insight, but also a temporal extensibility given the possibility of reevaluating its content.

At the start of the twentieth century, Croatian doctors were predominantly interested in less known or new diseases. New developments in the area of endocrinology, for example, turned the attention of medical community to the diseases for which the cause was previously unknown, and such cases were frequently accompanied with photographs. A good example is the first case of a patient with acromegaly (Fig. 7).³⁹ Both photographs show the same patient hospitalized in Osijek in 1894 due to severe rheumatic pain in both knees and a tumor on the right side of his skull and face. The first photograph shows the head and upper torso of a patient dressed in striped pajamas with arms crossed at his chest. On the patient’s face there are tumorous growths with those on the left side deforming his ear and face, pulling the left corner of the mouth and moustaches downward. The patient is expressionless and focused on the photographer, while the fists are big and altered. The second photograph shows the lower part of the patient’s body who is now sitting on the chair in order to provide a better view of his legs that show enlarged joints, particularly knees.

If this case had been published without photographs it would have entered Croatian medical history as the first documented case of acromegaly. However, it is precisely the inclusion of photographs that allows for an alternative explanation from today’s vantage point informed by contemporary notions on this disease. While for the author the photographs are a clear proof of acromegaly, doctors today would note how the patient’s face is deformed by tumorous growth and does not convey a typical expression

37 Partsch, “Obesitas”.

38 Barthes, *Camera Lucida*.

39 Ćulumović, “Akromegalia”.

of a patient with acromegaly, which involves the development of rougher facial features due to the enlargement of bones and sinuses.⁴⁰ One of the tools available to the doctor in cases of suspected acromegaly are past photographs through which a change in appearance could be ascertained. The author did not mention this diagnostic tool and given the fact that photography at the time was not widely available, it was probably technically unfeasible to follow the patient’s disease by photographing him for several years. All these factors retrospectively throw doubt on the original diagnosis, for in this case, and in accordance with Barthes’ notion of photography as a temporal hallucination,⁴¹ it is precisely the photograph itself which enables us to reevaluate this case as the first description of acromegaly in Croatia.

Unlike the previous photographs, which attempted to highlight the changes that supposedly point to acromegaly, the next two photographs of patients with pellagra—a disease caused by inadequate uptake of niacin (vitamin B3)—are much worse in revealing its typical symptoms (Fig. 8). Proper visualization of skin changes characterizing pellagra would require a focused view of such spots, so it is evident that the author was not concerned with proving his diagnosis in these cases, but rather with establishing the time span of the disease. The caption under the photographs thus states: *pellagra lasts for 5 years* and *pellagra lasts for 3 years*.⁴² In any case, the complex relationship between photography and time is revealed, with time being an important framework through which to observe and follow the development of the disease.

Unlike the case of acromegaly, where doctors unfortunately did not possess a patient’s photograph prior to the advent of his disease, in the case involving a patient suffering from myasthenia they used a series of photographs to establish a timeline of the disease and its remission.⁴³ The photograph, which dominates the article with its central position on the first page, depicts a man in an urban suit from the beginning of the twentieth century (Fig. 9). The photograph from 1906 reveals the bilateral ptosis, myopathic forehead and extensive weakness of the extraocular muscles.⁴⁴ Apart from this photograph, several others were printed in the article. One, reprinted from foreign literature, shows a patient with ptosis with a

40 The enlargements of supraorbital arches and the nasal base are typical signs of acromegaly. Nasolabial fold and lips thicken. Acromegaly also leads to mandibular prognathism and malocclusion. Distance between teeth becomes more visible. All these features are lacking on the photograph.

41 Barthes, *Camera Lucida*, 115.

42 Ćulumović, “Pellagra”, 420.

43 Myasthenia gravis is an autoimmune disease characterized with muscle weakness due to the destruction of acetylcholine receptors mediated by antibodies and cellular immunity.

44 Gutschy, “Slučaj”.

picture of microscopic preparation of the affected muscles, and the other represents the same photograph from the front page, now reduced in size and accompanied with a photograph of a patient during previous remission. When observing those two photographs, a reader gains insight into the patient's normal appearance and that affected by the disease, as noted by the author of the case report: "This can best be observed by comparing the myasthenic facial expression of our patient now with that during remission after the year 1902 (photographed from the medallion)".⁴⁵ This case thus represents the first use of photography in comparing the patient's condition during remission and with active disease.

PHOTOGRAPHY AS A TOOL FOR AFFIRMING MEDICAL SPECIALTIES

During the first half of the twentieth century many medical specialties used photography as a tool for one's own affirmation. Unsurprisingly, many case reports containing photographs were published by the representatives of rather young specialties. Out of 251 cases accompanied by photographs in the analyzed period, 64 were orthopedic cases. The person most responsible for the introduction of photography to orthopedics was Božidar Špišić, one of the pioneers of medical photography in Croatia. Already during the First World War, Špišić extensively photodocumented the rehabilitation and resocialization of injured war veterans.⁴⁶ By doing so, he inspired a whole generation of younger orthopedists such as Mato Šarčević and Vladimir Čepulić, who followed his lead and took photographs of their more interesting cases and thus underscored the importance of their own profession. Given that orthopedics originally arose out of the need to correct various deformities in children, Špišić frequently published pediatric cases. His argument was that by publishing clinical reports, medical community would be able to better understand the causal nature of various disorders:

Because of this reason, it is important and useful to publish even the simplest cases to the medical public, because by multiplying casuistry we would become better at understanding the nature and causes of such congenital malformations. This is valid even more so in those cases which, after detailed research, enable us to determine not only the factors which caused such deformities, but also to establish the precise time when these factors started to exert their influence or became ineffective.⁴⁷

With this kind of thinking, Špišić regularly published photographs with articles on a wide range of topics, such as the developmental dislocation

45 Ibid., 131.

46 Špišić, *Kako pomažemo našim invalidima*.

47 Špišić, "Prirodjene mane".

of the hip,⁴⁸ tuberculosis of the knee,⁴⁹ scoliosis,⁵⁰ knee contractures,⁵¹ rickets,⁵² and others (Fig. 10). It was of utmost importance to him to stimulate a moral and professional evolution in regards to the disabled body and to redefine its value according to the capability to perform physical work. According to Špišić, medicine was there to help achieve this goal and thus help in building a healthy and prosperous nation.⁵³

Such an understanding of orthopedics as a specialty rooted in social medicine as much as in clinical, curative practice, was present throughout Špišić's career. It is through this lens that one should approach his description of *hallux varus*, a congenital malformation that he presented in *Liječnički vjesnik* using three examples from his clinical practice.⁵⁴ According to Špišić, the causes of this abnormality are both endogenous (hereditary factors, syphilis, alcoholism) and exogenous (abnormal fetal position, inflammation, amniotic band syndrome). Although his everyday work mostly involved individualized clinical practice far away from public health issues, Špišić presented this anomaly as a direct proof of the importance of a state fight against widespread alcoholism. Namely, Špišić claimed that in all three cases of children with *hallux varus*, their fathers were "in true sense dipsomaniacs".⁵⁵ In interwar period, when syphilis, tuberculosis and alcoholism were considered to be the most troubling public health issues capable of weakening the nation's biological capacities, Špišić's social-medical orthopedics demonstrated the correlation between social diseases and their clinical manifestations and affirmed the power of his profession to correct abnormalities. It thus positioned orthopedics as an indispensable element within more general healthcare reforms of his time.⁵⁶

A similarly broad view characterized ophthalmology as well, a profession which profusely used photography to demonstrate interesting clinical cases and educated readers about the potential causes of ocular diseases. The first color photograph published on the pages of *Liječnički vjesnik* in 1906 arose from the ophthalmological practice (Fig. 11). It was a reproduction made in collotype by the Mosinger company in Zagreb,⁵⁷ for

48 Špišić, "Liječenje kongenitalne luksacije kuka".

49 Špišić, "Naše liječenje".

50 Špišić, "O skoliozi".

51 Špišić, "Ortopedsko-kirurško liječenje".

52 Špišić, "Prilog operativnom liječenju".

53 Osten, "Photographing Disabled Children".

54 Špišić, "Hallux varus".

55 Ibid., 92.

56 Fatović-Ferenčić, Kuhar, "Photography in the Rehabilitation".

57 Mosinger company was founded by the Collotype department (Svjetlotiskarski zavod) in 1899, and in 1904 a lithography section was also established.

which ophthalmologist Vladimir Katičić stated: “I should thank professor Haab in Zürich and Lehman publishing house in München for their kindness with which they allowed me to reproduce these pictures, and also the government for their generosity in paying for the expenses.”⁵⁸ As an oldest medical specialty, ophthalmology was well-established already at the beginning of the twentieth century. Its strong position within the medical system and its broad view on the questions of population health was evident through its treatment of trachoma, a prevalent eye infection caused by the bacterium *Chlamydia trachomatis*.⁵⁹ Ophthalmology approached the topic of trachoma through a social medicine lens, trying to emphasize the importance of changing unhygienic customs prevalent in the population, especially in the rural areas:

Given that the major part of our population, including the substantial part of our intelligentsia, unfortunately does not comprehend the importance of trachoma and its severe consequences, and given that as physicians we are still not in a position to gain experience about trachoma and similar diseases at special medical courses, I will try with these words and additional pictures to contribute with my modest abilities to reduce the aforementioned shortcomings.⁶⁰

Given the scarcity of ophthalmology atlases, Katičić included the photographs in his articles, arguing that “even the most schematic picture contributes greatly to better understanding and memory”.⁶¹ As a specialty dealing with sight and vision, it is only natural that the ophthalmologists would seek to document visual aspects of their profession. Interestingly, after his specialization in Vienna, Kurt Hühn, the son of a prominent Zagreb lithographer and photographer Julije Hühn, worked at the Sisters of Mercy Hospital in Zagreb as the head of the Department of Ophthalmology (1903–1940). Sadly, we could not find any photograph of his patients on the pages of *Liječnički vjesnik* in the analyzed period.⁶²

As with many other medical specialties, ophthalmology gained traction with the establishment of the School of Medicine in Zagreb in 1917. On the fifth anniversary of the opening, a monograph was published celebrating the work done in this short period, with several clinics opting to include

58 Katičić, “Prilog”.

59 Trachoma is an infection of the eye caused by the bacterium *Chlamydia trachomatis* and represents the leading cause of blindness due to infectious diseases in the world.

60 Katičić, “Prilog”, 1.

61 Ibid.

62 Hühn was mostly interested in the Röntgen radiation, given that the Sisters of Mercy Hospital was the first in Zagreb to procure the X-ray machine (1901). Already in 1902, Hühn treated ulcerated breast cancer with X-rays, and published first X-ray images ever printed in *Liječnički vjesnik*.

a wealth of photographs.⁶³ Unlike other clinics, whose photographs were mainly taken by amateurs, the visual representation of the Department of Ophthalmology was left to the famous Zagreb photo atelier Foto Tonka run by Antonija Kulčar. Albert Botteri, the head of the Department at that time, undoubtedly wanted to represent his clinic, the first of its kind in the region, as an institution dedicated to functional organization, specialization and recognition, and as a mirror of his own competence in equipping it in the mold of distinguished European centers.⁶⁴

When exploring the role of photography in the context of affirming the position of young medical specialties within broader medical system, a particularly interesting place belongs to neuropsychiatry, for it was at the end of the nineteenth and the beginning of the twentieth centuries that the brain was understood as the seat of many mental disorders. Doctors tried to establish the correlations between organic changes in the brain on the one hand and mental disorders and neurologic symptoms on the other, while photography was used to objectivize the spotted changes.

Despite this general trajectory of the development of neuropsychiatry, articles published in *Liječnički vjesnik* were rarely accompanied with photographs. One exception was a case of one insane pastor, which featured a photograph of his brain (Fig. 12). It was confirmed during autopsy that the patient suffered from a brain tumor and the doctors concluded that it was the cause of this patient’s psychiatric symptoms.⁶⁵ By reducing psychiatric symptoms to the changes in brain anatomy, neuropsychiatry utilized photography to position itself among other empirically grounded medical specialties.⁶⁶

A photograph of the brain was also included in an article by psychiatrist Aleksandar Kuljženko, who described cases of frontotemporal dementia, i.e., the limited atrophy of cerebral cortex.⁶⁷ Photographs of brains rather than patients made it clear that the cognitive apparatus was biologically determined, thus placing psychiatry in a system far removed from the abstract (the soul) and into the concrete (the brain).

One of the most widely used photographic strategies that we have identified in *Liječnički vjesnik* and which were used to demonstrate contemporary therapeutic possibilities, were photographic sequences. Photographic documentation and medical narratives which follow it travel through time, allowing us a view into the past. Although a snapshot is instant, photography is sometimes temporalized through a process which points to

63 Anonymous, “Sveučilišne ustanove”.

64 Fatović-Ferenčić, “The Eye Clinic’s Visual History”.

65 Stanojević, “Katamnistički pregled”.

66 Kuhar, Fatović-Ferenčić, “Začetci i razvoj hrvatske psihijatrije”.

67 Kuljženko, “O ograničenim atrofijama”.

the different phases of a disease or its therapeutic management. Among the photographic sequences, one which stands out involves a case of an 18-year-old primipara from Opatija who gave birth to a child without the help of either a doctor or a midwife. Due to very strong labor pains her posterior vaginal wall and perineum ruptured and the child was delivered through this newly-formed passage which later got infected. The article is accompanied with one schematized drawing in order to elucidate the anatomical relationships, and three photographs taken from close range. The first shows the patient's condition upon the arrival to the clinic, the second after the perineal bridge fell off, and the third after plastic surgery. The temporal sequence established through photography allows for a complete reconstruction of the course of the disease and the therapeutic management.⁶⁸ This case, which included a photograph of a patient during recovery, differs from the usual before and after pictures used in the overwhelming majority of cases of photographic sequences. With the inclusion of a third photograph, the readers were given an even more plastic visualization of what they could expect during the management of similar cases.

Many other medical specialties published photographic sequences. A particularly rich material was published by Juraj Körbler from the Department for Treatment with Radium in 1934, who published 12 photographs depicting six patients before and after treatment with radium in various techniques (Fig. 13). His goal was to demonstrate the power of modern radiotherapy to spare healthy tissue and target the diseased.⁶⁹ Generally speaking, photographic sequences were focused much more on the competence of a physician and his therapeutic capabilities than on the disease itself. Thus, photography revealed the complex relationship between disease and time, through which it was increasingly visualized.

CONCLUSION

Our screening of photographs published in *Liječnički vjesnik* from 1877 to 1950 yielded 251 instances of medical casuistry. The photographs accompanied, among others, the first descriptions of new diseases, tumors, congenital anomalies and epidemic diseases. When looking at these photographs from today's vantage point, it has increasingly become clear to us that by showing the changed, deformed or misshapen bodies, subjected to specific clinical gaze, therapy and rehabilitation, the doctors were concerned with mapping and establishing the national pathology. The main incentive was to document these cases for posterity, or, in the words of one physician from the beginning of the twentieth century, "to photograph the child with this congenital malformation, so that the case would be

68 Zanela, "Ruptura".

69 Körbler, "Liječenje raka kože".

preserved on the pages of *Liječnički vjesnik*".⁷⁰ By publishing the photographs, the doctors wanted to foster the discussion on certain topics and to visually compare local cases with foreign literature. The photographs opened up the possibility of a more detailed questioning of proposed classifications of diseases and establishing new nosologic entities. In an era of poor availability of adequate visual teaching aids, photography became a popular medium due to its visual representation of clinical signs and therapeutic procedures. It recorded the process of treatment in all its stages and impressively displayed doctors' valiant efforts to successfully rehabilitate their patients.

Most of the photographs published in *Liječnički vjesnik* at the end of the nineteenth and in the first half of the twentieth centuries display a lack of technical quality and sometimes even a poor focus on the features of a disease represented on them. This can be attributed to the fact that medical institutions only exceptionally hired professional photographers. Unlike in other countries, these photographs were almost exclusively made in a hospital setting and taken by amateurs, so they cannot be used to evaluate the possible role the commercial photography played in the development of medical photography.⁷¹ Poor quality of these photographs can also be ascribed to the lack of specific instructions for authors regarding the necessary quality of photographs intended for publication, their number, dimensions or captions.⁷² In financially difficult times, such as those immediately after the Second World War, the editorial board of *Liječnički vjesnik* even suggested to the authors to keep the number of photographs to a minimum, otherwise they would have to participate in covering the expenses for their printing.⁷³ Therefore, it can safely be assumed that most of the photographs were taken from medical archives, while only a lesser number was made exclusively for the articles intended to be published in the journal.⁷⁴

Not only were the photographs not authored in most cases, but also the techniques used in making them were mentioned only in extremely rare instances. Such exceptions are the first color photographs of trachoma published by Vladimir Katičić, and an article penned by the neuropsychiatrist Franjo Gutschy from 1897, in which there is a caption stating that the photograph is "an autotypy made by V. I. Margetić in Zagreb".⁷⁵ As the

70 Culek, "Prirodjeni rasejep".

71 Freeland, "Portraits".

72 The first Instructions for Authors were published in *Liječnički vjesnik* in 1922.

73 See, for example, Anonymous, "Upute", 58.

74 The founder of clinical photography in Croatia, the orthopedist Božidar Špišić, mentions a photographer in his Department of Orthopedics, but does not mention his name. The photographs made for Špišić are unsigned.

75 Gutschy, "Slučaj porencephalije".

author himself states, it is a “photogram” of a patient with cerebral palsy, made by Vaso Margetić in relief printing.⁷⁶

Photographs accompanying the cases published in *Liječnički vjesnik* were either printed alone or in combination with photographs of other patients or the same patient after therapy (as comparative material and/or to evaluate the treatment), X-rays (to better visualize the internal changes), photographs of micro- and macropreparations (most often with pathological or microbiological expertise) and schematic or artistic drawings (for better understanding of topography and anatomical relationships). The position of photographs also changed: at first, they were published together with text, but from 1924 to 1934 all the photographs were printed at the end of each issue on a glossy white paper.

Despite the fact that almost all medical specialties in the first half of the twentieth century used photography to document therapeutic methods at their disposal or to record otherwise interesting cases, certain specialties such as orthopedics, otorhinolaryngology, ophthalmology, gynecology and infectious diseases dominated (Table 1). It is interesting to note that among infectious diseases presented with photographic material, rare manifestations of certain diseases such as endemic syphilis were favored instead of those most commonly found.⁷⁷ For example, we were unable to detect a single photograph showing diphtheria, cholera, scarlet fever, smallpox, chickenpox, malaria and typhus, which were some of the most prevalent and deadly acute infectious diseases at the time. We suspect that this is due to the fact that their clinical manifestations were known among medical personnel, so doctors rather opted to address them with graphs and other methods used in epidemiological research. There is also a relative lack of cases dealing with internal diseases, which can be explained with the fact that they only sometimes express themselves in a way accessible to the camera. On the other hand, it was somewhat puzzling to note that in the whole analyzed period only one forensic case was accompanied with a photograph. The case deals with violent suffocation and the photograph shows petechiae on the palate.⁷⁸ In any case, the frequency of photographs does not seem to correlate with real incidence of certain diseases, but with other factors such as their rarity and success in treatment.

The photographs analyzed in this paper confirmed their role and influence in terms of their documentary and academic value. Certain photographs also confronted us with a question whether a photograph of an ill person that is a hundred years old can still convey a moral message or elicit moral

76 During that time, Margetić operated his collotype and heliographic business at 16 Franz Joseph Square in Zagreb (today 18 King Tomislav Square). See, Gržina, *Sunčani kip*, 253.

77 Grin, “Primarni afekt”.

78 Premeru, “Pokušaj umorstva”.

response. Susan Sontag, for example, claims that old photographs betray the fact that “the ethical content of photographs is fragile.”⁷⁹ Writing from a more philosophical perspective, Roger Scruton totally rejects the possibility that photographs represent reality.⁸⁰ On the other hand, with a much more compatible view to our own, Stephanie Ross stated that photographs can communicate ethical values through emotions stimulated by viewing them.⁸¹ We would also add that the photograph can also accomplish this through the understanding of its ethos, which in our case stems from the relationship between their content and our knowledge on the history of human rights. Thus, these photographs do not only play a role as documents of a past medical reality, but also point to the ways patients were exposed, gazed upon and represented by the doctors. Although already at the beginning of the nineteenth century, a letter to the editor of *The New York Medical Journal* spurred a discussion on the protection of patients’ privacy, our set of photographs demonstrates a lack of care in this respect.⁸² They suggest a thoughtless, even needless exposure of various body parts to a photographer, regularly without any measures to protect the patients’ identities.⁸³ Sometimes the patients, mostly children, were totally naked, while at other times female patients covered only their heads with their clothes. One exception are the photographs of a female patient who was treated with new chemotherapeutic agent Rubrophen in *Čakovec* for extrapulmonary tuberculosis.⁸⁴ Photographs show a patient with skin changes on hands and on a stump. On all the photographs the patient uses her arms to hide her face. Even if based on the first two photographs one could claim that this position was taken to better visualize skin changes, the third photograph, which shows the patient after successful treatment, wholly invalidates this argument (Fig. 14).

Unlike classic portraits made for civil purposes, portraits in medical photography are not symbolic acts emphasizing its own importance,⁸⁵ but are rather concerned with documentation. Patient suppresses his or her personality, subjective preferences and a tendency to pose, and becomes an object of observation and manipulation not only in the process of medical diagnosis and treatment, but also during photographing. According to Susan Stewart, “the real itself is offered to the viewer, rather than a version of the real being given by a subject with his or her own desires, prejudices, and so on.”⁸⁶ The relationship between the patient and the doctor was

79 Sontag, *On Photography*, 16.

80 Scruton, “Photography and Representation”.

81 Ross, “What Photographs Can’t Do”.

82 Anonymous, “Indecency”.

83 In the articles, patients are mostly addressed with initials or even full names, location and sometimes their vocation.

84 Brodnjak, “Slučaj tbc. luposa cutis”.

85 Freund, *Fotografija i društvo*.

86 Stewart, *On Longing*, 138.

paternalistic and the patients were treated as objects of medical manipulation. The doctor was superior with his knowledge and social standing, while the patient occupied a submissive position in the hope of being cured. As Margaret Lock states, “any connection between knowledge and practice remains essentially obscure, as does the problem of individual meanings attributed to cultural symbols and their manipulation, related in turn to relationships of power”.⁸⁷ Photographs analyzed here reflect the era in which power was mostly in the hands of doctors, signaling practices which we clearly recognize as unacceptable today.

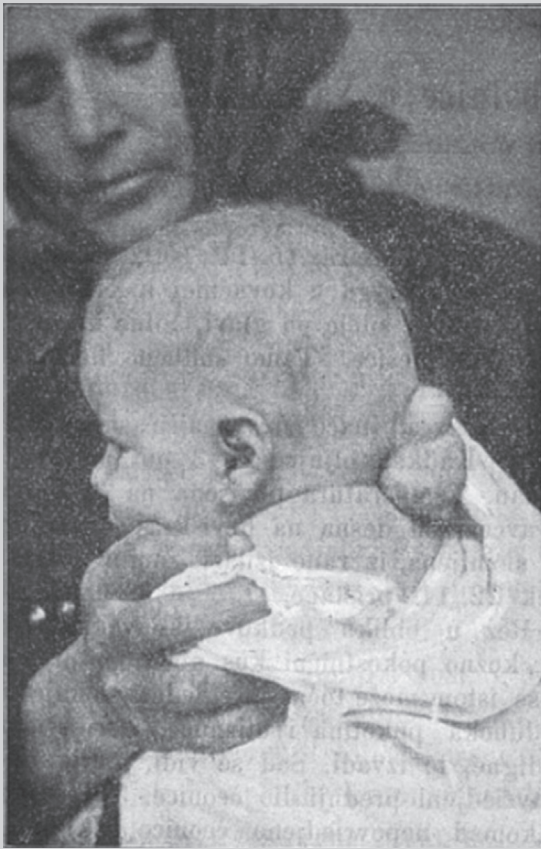Decade	1880–89	1890–99	1900–09	1910–19	1920–29	1930–39	1940–49	Total by specialties
Orthopedics	1		1	17	13	21	11	64
Internal medicine		2	2	5		4	4	17
Gynecology		2	2	1	2	9	5	21
Neuropsychiatry		1	1	1	1	4	3	11
Pathology		1		1				2
Surgery		1	7	5	12	8	14	47
Pediatrics			2			2	8	12
Infectious diseases				5	2	7	6	20
Ophthalmology					8	1	19	28
Dermatology					1	13	10	24
Balneology					1			1
Oncology						2	1	3
Forensic medicine						1		1
Total by decades	1	7	15	35	40	72	81	251

87 Lock, “Cultivating the Body”, 136.

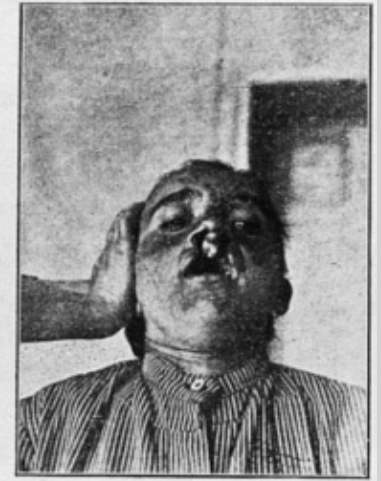BIBLIOGRAPHY

- Anonymous. “Indecency in photography”. In: *The New York Medical Journal* 59 (1894): 724–725.
- Anonymous. “Sveučilišne ustanove u Medicinskom fakultetu”, 162–175. In: *Sveučilište Kraljevine Srba, Hrvata i Slovenaca u Zagrebu 1874–1924: Spomenica Akademickoga senata*. Dragutin Boranić, ed. Zagreb: Zaklada tiskara Narodnih novina, 1925.
- Anonymous. “Upute saradnicima”. In: *Liječnički vjesnik* 69, No. 1-2 (1947): 58.
- Antolković, Josip. “Molluscum pedis cum nuce ossea”. In: *Liječnički vjesnik* 9 (1887): 1-3
- Barthes, Roland. *Camera Lucida: Reflections on Photography*. New York: Hill and Wang, 1981.
- Brauer, Fae. “Capturing Unconsciousness: The New Psychology, Hypnosis, and the Culture of Hysteria,” 243–262. In: *A Companion to Nineteenth-Century Art*, ed. Michelle Facos. Hoboken: Wiley Blackwell, 2019.
- Brkić Midžić, Silvija, Fatović-Ferenčić, Stella. “Vizualni identitet Liječničkog vjesnika od osnutka 1877. godine do danas”. *Liječnički vjesnik* 145 (2022): 173–189.
- Brodman, Estelle. *The Development of Medical Bibliography*. Baltimore: Medical Library Association, 1954.
- Brodnjak, Mirko. “Slučaj tbc. luposa cutis izliječen Rubrophenom”. *Liječnički vjesnik* 61, No. 3 (1939): 185–186.
- Car, Andrija. “Beitrag zum Sarkom der Orbita”. *Liječnički vjesnik* 47 (1925): 736–742.
- Culek, Antun. “Dr. F. Dostal: Pseudohermafroditismus externus žensky”. *Liječnički vjesnik* 35 (1913): 622.
- Culek, Antun. “Prirodjeni rascjep križne kosti s novotvorinom”. *Liječnički vjesnik* 36, No. 11 (1914): 529–530.
- Ćulumović, Pavao. “Akromegalia”. *Liječnički vjesnik* 18 (1896): 8–14.
- Ćulumović, Pavao. “Pellagra (Svršetak)”. *Liječnički vjesnik* 21 (1899): 419–426.
- Diamantis, Aristidis, Magiorkinis, Emmanouil, Androustos, George. “Alfred François Donné (1801–78): a pioneer of microscopy, microbiology and haematology”. *Journal of Medical Biography* 17, No. 2 (2009): 81–87.
- Didi-Huberman, Georges. *Invention of Hysteria: Charcot and the Photographic Iconography of the Salpêtrière*. Cambridge: The MIT Press, 2003.
- Fatović-Ferenčić, Stella, Brkić Midžić, Silvija. “Tuberkuloza i naličje grada: fotografije zagrebačke stambene bijede iz zbirke Vladimira Čepulića”. *Liječnički vjesnik* 142 (2020): 420–429.
- Fatović-Ferenčić, Stella, Brkić Midžić, Silvija. “Vizualna memorija struke – pogled na fotoalbume otorinolaringološke klinike sačuvane u Hrvatskom muzeju medicine i farmacije HAZU”. *Liječnički vjesnik* 143 (2021): 310–318.
- Fatović-Ferenčić, Stella, Kuhar, Martin. “‘Images from our Orthopedic Hospital’: Photography in the Rehabilitation of Disabled War Veterans in Croatia During the First World War”. *International Orthopaedics* 45 (2021): 1109–1115.
- Fatović-Ferenčić, Stella, Kuhar, Martin. “‘We Live in a Wagon Never Going Anywhere:’ The Representations of Housing Conditions and Tuberculosis in Zagreb between the Two World Wars”. *Photography and Culture* 15 (2022): 109–128.
- Fatović-Ferenčić, Stella, Pećina, Marko. *Iz Florschützova okvira: Kirurg Vatroslav Florschütz (1879. – 1967.) riječju i slikom*. Zagreb: HAZU, KBC Osijek, 2011.
- Fatović-Ferenčić, Stella, Prgomet, Drago. *Vizualna memorija struke – Klinika za bolesti uha, nosa, grla i kirurgiju glave i vrata Medicinskog fakulteta Sveučilišta u Zagrebu u povodu stoljeća njezinog postojanja (1921. – 2021.)*. Zagreb: HAZU, Medicinski fakultet Sveučilišta u Zagrebu, 2021.

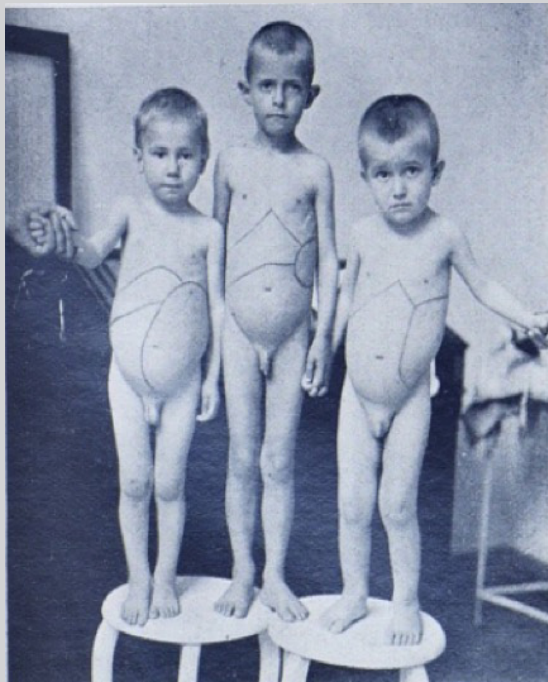- Fatović-Ferenčić, Stella. "The Eye Clinic's Visual History: Zagreb School of Medicine University of Zagreb Ophthalmology Clinic in Accordance with the Preserved Photographic Archive". *Život umjetnosti* 109 (2021): 66–85.
- Fatović-Ferenčić, Stella. *Liječnički vjesnik – medicinska komunikacija i memorija struke*. Zagreb: Hrvatski liječnički zbor, 2022.
- Freeland, Cynthia. "Portraits in Painting and Photography." *Philosophical Studies* 135, No. 1 (2007): 95–109.
- Freund, Gisèle. *Fotografija i društvo*. Zagreb: Grafički zavod Hrvatske, 1981.
- Grgić, Dražen, Pentz, Ante, Mandić, Zdravko. "Digital Imaging in Ophthalmology". *Acta clinica Croatica* 41, No. 4 Suppl – OPTHALMOL (2002): 33–37.
- Grgić, Marko Velimir, Pastorčić Grgić, Marija. "Slikovna dokumentacija u medicini". *Liječnički vjesnik* 144 (2022): 416–417.
- Grin, Ernest. "Primarni afekt kod endemičnog sifilisa u Bosni". *Liječnički vjesnik* 51(Suppl.3) (1929): 1.
- Gržina, Hrvoje. *Sunčani kip: povijest fotografije u Zagrebu 1839. – 1900*. Zagreb: Hrvatski državni arhiv, 2022.
- Gutschy, Franjo. "Slučaj myasthenične pseudo-paralyze". *Liječnički vjesnik* 29 (1907): 129–132.
- Gutschy, Franjo. "Slučaj porencephalije kod cerebralne djetinje uzme". *Liječnički vjesnik* 19, No. 2 (1897): 55.
- Hannavy, John, ed. *Encyclopedia of Nineteenth-Century Photography*, Vol 1. New York: Routledge, 2008.
- Hustvedt, Asti. *Medical Muses: Hysteria in Nineteenth-Century Paris*. New York: W. W. Norton & Company, 2011.
- Katičić, Vladimir. "Prilog diagnozi trachoma". *Liječnički vjesnik* 28, No. 1 (1906): 1–5.
- Körbler, Juraj. "Liječenje raka kože i kožnih bolesti radijem". *Liječnički vjesnik* 56, No. 1 (1934): 23–35.
- Krmpotić, Mario. "Endemija kala-azara na jugoistočnoj obali Jadrana". *Liječnički vjesnik* 56 (1934): 38–45.
- Kuhar, Martin, Fatović-Ferenčić, Stella. "'Liječnik bolesnih duša': začetci i razvoj hrvatske psihijatrije kroz ulogu i djelovanje Ive Žirovčića". *Studia lexicographica* 10, No. 1 (2016): 129–149.
- Kuljženko, Aleksandar. "O ograničenim atrofijsama mozgovne kore". *Liječnički vjesnik* 59, No. 3 (1937): 91–95.
- Lock, Margaret. "Cultivating the Body: Anthropology and Epistemologies of Bodily Practice and Knowledge". *Annual Review of Anthropology* 22 (1993): 133–155.
- Maixner, Ivan. "Kazuistika iz gradske bolnice u Varaždinu: Meningocele occipitalis inferior". *Liječnički vjesnik* 25 (1903): 82.
- Marušić, Matko, Marušić, Ana. "Ratna fotografija u medicini". *Medijska istraživanja* 10 (2004): 107–116.
- Mayerhofer, Ernest, Dragišić, Branko. "Raširenost Kala-azara u Jugoslaviji". *Liječnički vjesnik* 57 (1935): 506–509.
- Milam, Emily C., Ramachandran, Sarika. "19th Century Dermatologic Atlases in the Early Age of Photography". *JAMA Dermatology* 151 (2015): 969.
- Neuse, Wilfried H. G., Neumann, Norbert J., Lehmann, Percy, Jansen, Thomas, Plewig, Gerd. "The History of Photography in Dermatology: Milestones from the Roots to the 20th Century". *Archives of Dermatological Research* 132 (1996): 1492–1498.
- Osten, Philipp. "Photographing Disabled Children in Imperial and Weimar Germany". *Cultural and Social History* 7 (2010): 511–531.
- Parent, André. "Duchenne De Boulogne: A Pioneer in Neurology and Medical Photography". *The Canadian Journal of Neurological Sciences* 32 (2005): 369–377.
- Partsch, Franjo. "Slučaj 'obesitas universalis'". *Liječnički vjesnik* 15 (1900): 40–42.
- Pasquali, Paola. "History of Medical Photography", 47–72. In: *Photography in Clinical Medicine*, ed. Paola Pasquali. Cham: Springer, 2020.
- Premeru, Eugen. "Pokušaj umorstva gušenjem rukama". *Liječnički vjesnik* 58, No. 7 (1936): 302–303.
- Rogers, Blair O. "The First Pre- and Post-Operative Photographs of Plastic and Reconstructive Surgery: Contributions of Gurdon Buck (1807–1877)". *Aesthetic Plastic Surgery* 15 (1991): 19–33.
- Rosen, George ed. "Medicine and Early Photography". *Ciba Symposia* 4 (1942): 1330–59.
- Ross, Stephanie. "What Photographs Can't Do". *The Journal of Aesthetics and Art Criticism* 41, No. 1 (1982): 5–17.
- Scruton, Roger. "Photography and Representation", *Critical Inquiry* 7, No. 3 (1981): 577–603.
- Senta Marić, Ankica. "Arhivska građa i fotodokumenti vezani uz rad Higijenskog zavoda u Splitu pohranjeni u Školi narodnog zdravlja 'Dr. Andrija Štampar'", 130–136. U: 90 godina u službi zdravlja. Od Higijenskog zavoda u Splitu do Nastavnog zavoda za javno zdravstvo Splitsko-dalmatinske županije, ed. Stella Fatović-Ferenčić. Split: Nastavni zavod za javno zdravstvo Splitsko-dalmatinske županije, 2012.
- Sontag, Susan. *On Photography*. New York: RossettaBooks, 1977.
- Summerly, Paula. "Medical Photography", 916–919. In: *Encyclopedia of Nineteenth-Century Photography*, Vol 1, ed. John Hannavy. New York: Routledge, 2008.
- Špišić, Božidar. "Hallux varus congenitus". *Liječnički vjesnik* 46, No. 3 (1924): 92–94.
- Špišić, Božidar. "Liječenje kongenitalne luksacije kuka kod posve male djece". *Liječnički vjesnik* 58, No. 7 (1936): 286–289.
- Špišić, Božidar. "Naše liječenje kontraktura i ankiloza kod tuberkuloze koljena". *Liječnički vjesnik* 58, No. 11 (1936): 465–469.
- Špišić, Božidar. "O skoliozi i njenom liječenju". *Liječnički vjesnik* 60, No. 7 (1938): 428–434.
- Špišić, Božidar. "Ortopedsko-kirurško liječenje teških kontraktura koljena". *Liječnički vjesnik* 52, No. 6 (1930): 241–246.
- Špišić, Božidar. "Prilog operativnom liječenju rahitičkih deformnih kostiju". *Liječnički vjesnik* 47, No. 4 (1925): 201–204.
- Špišić, Božidar. "Prirodjene mane femura i fibule." *Liječnički vjesnik* 40, No. 9 (1918): 285–297.
- Špišić, Božidar. *Kako pomažemo našim invalidima: slike iz naše ortopedijske bolnice i invalidskih škola*. Zagreb: Dionička tiskara, 1917.
- Stanojević, Laza. "Katamnestički pregled i nalaz autopsije u sudbenom slučaju umobolnog župnika Jerčića". *Liječnički vjesnik* 45, No. 10 (1923): 396–400.
- Stewart, Susan. *On Longing: Narratives of the Miniature, the Gigantic, the Souvenir, the Collection*. Baltimore: Johns Hopkins University Press, 1984.
- Toth, Jelica. "Kongenitalna ptoza i epikantus". *Liječnički vjesnik* 50 (1928): 473–476.
- Vodehnal, Josip. "Dva rijetka ginekološka slučaja". *Liječnički vjesnik* 57 (1935): 380–381.
- Walton, Kendall L. "Transparent pictures: On the nature of photographic realism". *Critical Inquiry* 11 (1984): 246–277.
- Wetzler, Sara. "Hugh Diamond, the father of psychiatric photography – psychiatry in pictures". *The British Journal of Psychiatry* 219, No. 2 (2021): 460–461.
- Zanela, Srećko. "Hermaphroditismus masculinus tubularis et externus". *Liječnički vjesnik* 53 (1931): 663–665.
- Zanela, Srećko. "Ruptura perinei centralis". *Liječnički vjesnik* 49, No. 10 (1927): 493–498.
- Zittlau, Andrea. "Pathologizing Bodies: Medical Portrait Photography in Nineteenth-Century America". *Amerikastudien / American Studies* 58 (2013): 543–558.



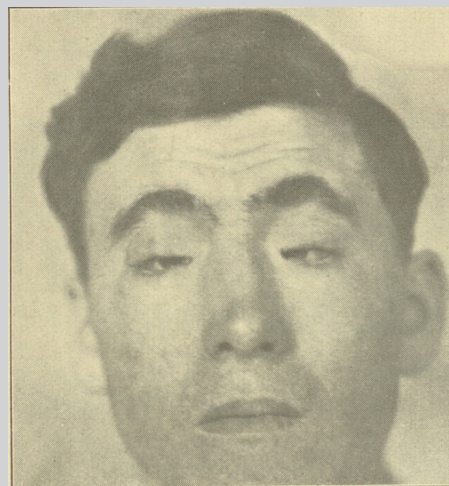
[1]



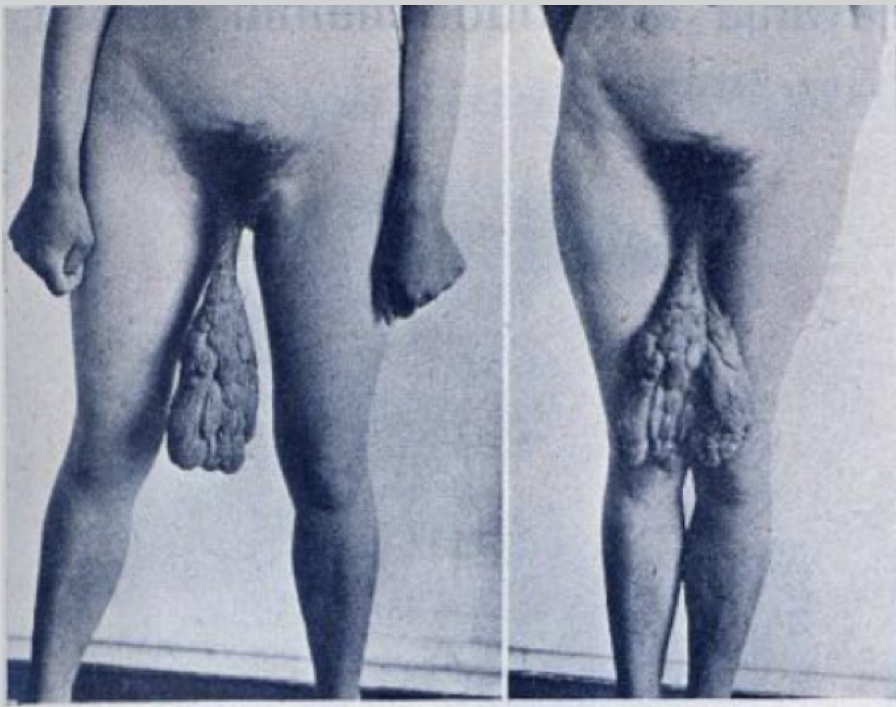
[3]



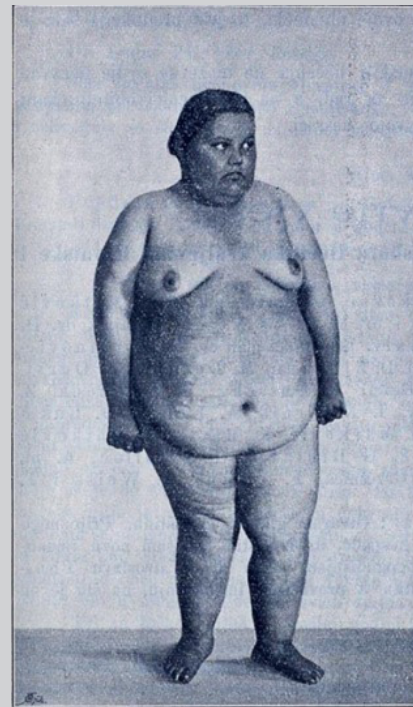[2]



[4]

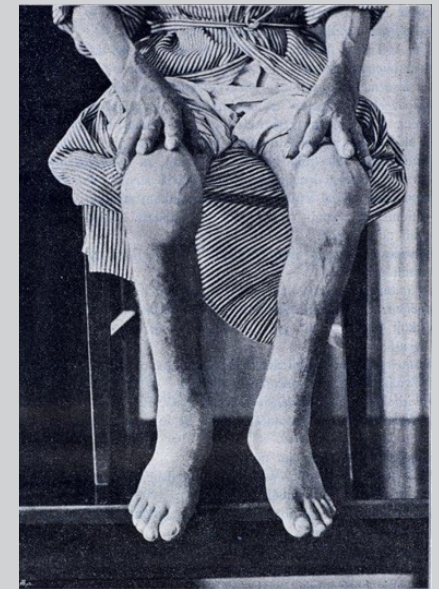
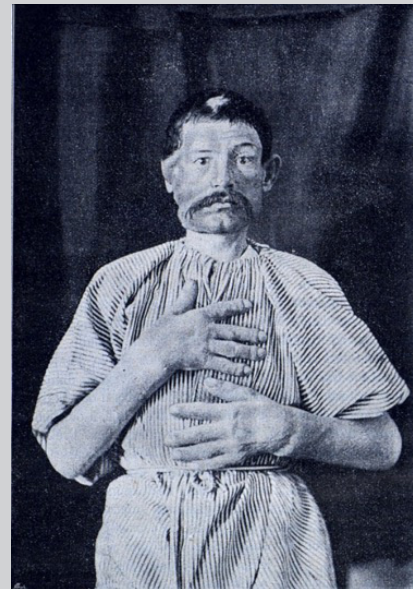

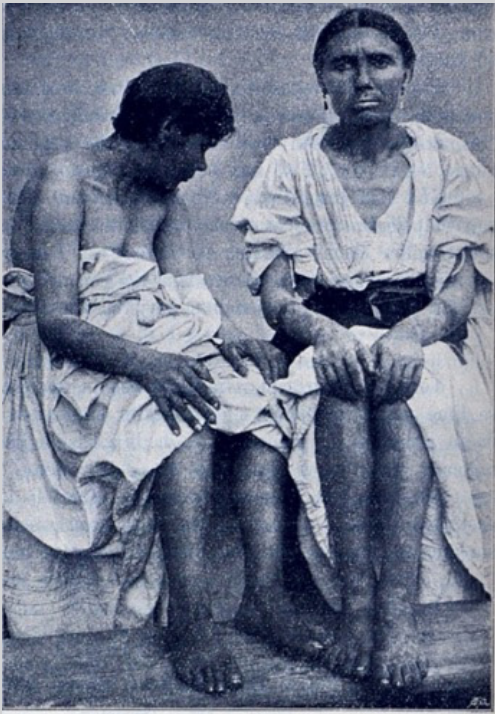[5]



[6]

[7]






5 god. Pellagra traje 3 god.

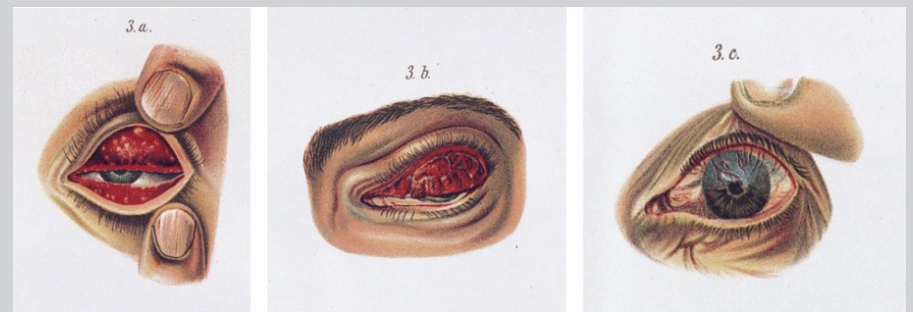
[8]



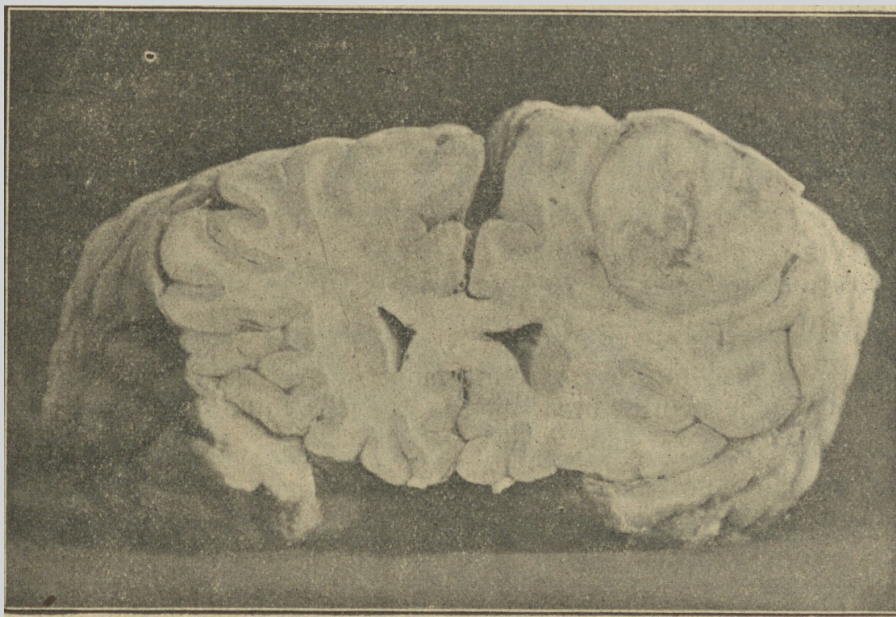
[9]



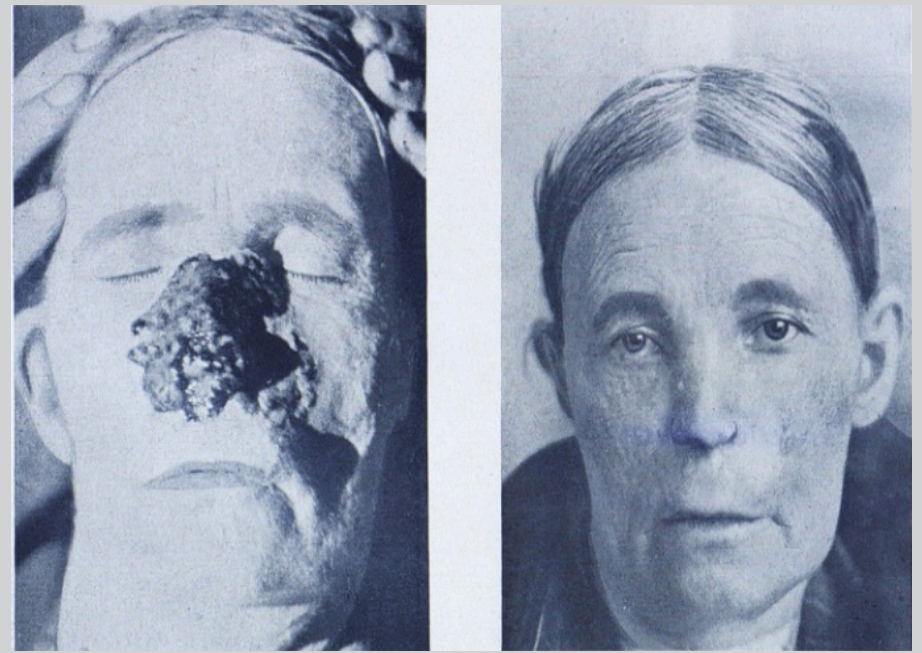[10]



[11]



[12]



[13]

1. Ivan Maixner, Occipital meningocele, 1903.
2. Mario Krmpotić, Three cases of kala-azar, 1934.
3. Ivan Maixner, Plastic surgeries of unilateral and bilateral cleft lips, 1920.
4. Jelica Toth, Congenital ptosis and epicanthus, 1928.
5. Josip Vodehnal, Two rare gynecology cases, 1935.
6. Franjo Partsch, Obesity, 1900.
7. Pavao Čulumović, Acromegaly, 1896.
8. Pavao Čulumović, Pellagra, 1899.
9. Franjo Gutschy, A case of myasthenic pseudoparalysis, 1907.
10. Božidar Špišić, Treatment of scoliosis, 1938.
11. Vladimir Katičić, Trachoma, 1906.
12. Laza Stanojević, Autopsy in the case of insane pastor Jerčić, 1923.
13. Juraj Körbler, Treatment of skin cancer with radium, 1934.
14. Mirko Brodnjak, Skin tuberculosis cured with Rubrophen, 1939.

[14]

